

Emerging trends in diagnostic ultrasound

Wg Cdr VG Vasishta* Sqn Ldr M Bhatia†

ABSTRACT

Ultrasonography is an imaging technique which utilizes high frequency sound generated by a piezoelectric crystal for insonating the organ to be imaged. The returning signal may be displayed in various modes like A, TM and the commonly used B mode, which represents a slice of tissue in Gray scale. Ultrasound is a noninvasive investigation requiring very little patient preparation. Doppler works on the principle of detecting blood flow by detecting a change in the frequency of sound reflected by the moving blood. Newer technologies have been introduced like harmonic imaging, microfine imaging, broad beam signal formatting with extended signal processing and 3D imaging which have vast potential and promise to provide better and more efficient methods of displaying diagnostic data.

IJASM 2001; 45(2) 95 to 100

Key Words : USG, Doppler, Harmonic Imaging.

Unlike X rays which were put to use the moment they were discovered ultrasonography(USG) has been notoriously slow in its medical evolution. The first attempt at practical application being made in the unsuccessful search for the Titanic in 1912. Successful medical applications began in the 1940s and early 1950s. Recent technological breakthroughs in diagnostic ultrasound have surpassed all expectations. These new technologies are so numerous and have been introduced in such

rapid succession that considerable confusion surrounds how these technologies work and how best they should be used.

* *Classified Specialist (Radiodiagnosis), IAM, IAF, Vimanapura, Bangalore-560 017.*

† *Trainee, Advance course Radiodiagnosis, Command Hospital (AF), Bangalore-560 017.*

The physics of ultrasound

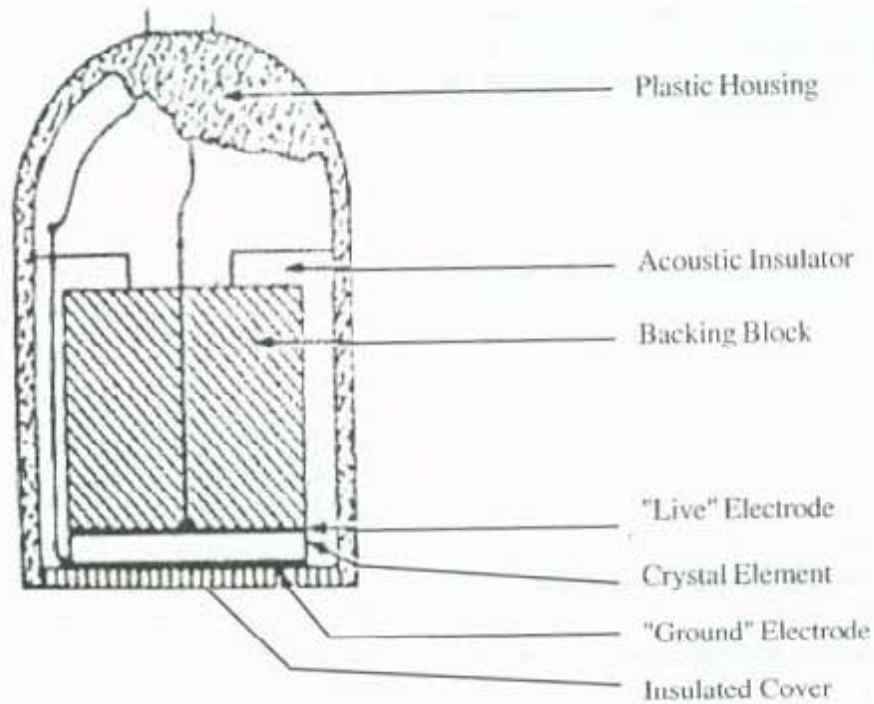
Ultrasound refers to the frequencies of sound above the audible range (>20,000 Hz). For medical imaging the frequencies employed are from 2 MHz to 20 MHz.

These frequencies are generated by means of piezoelectric crystal which is the main component of an ultrasound transducer. These crystals convert electric energy into sound waves. The crystal is made of lead-zirconate-titanate (PZT).

A thick crystal produces a low frequency sound while a thin crystal will produce a high frequency sound. While low frequencies like 3.5MHz achieve a better depth of imaging the higher frequencies like 7.5MHz give a better resolution. Thus the optimum imaging must utilize a frequency, which gives the maximum resolution at a given depth [1].

In X ray imaging the transmitted radiation blackens the film and creates the image. In USG it is the reflected portion of the beam which

Fig 1: Ultrasound Transducer



produces the image. The percentage of reflection by a tissue interface depends on its acoustic impedance and the angle of incidence of the beam. Acoustic impedance is the product of density and velocity of sound in a material and is measured in Rayls(CGS system).

As sound waves pass from one medium to another the amount of reflection is determined by the difference in the impedance of the two tissues. The greater the impedance the greater is the reflection of sound. The difference in the acoustic impedance between most body structures is small, the two notable exceptions being air and bone. Thus a soft tissue air interface or a soft tissue bone interface or totally reflects the sound beam

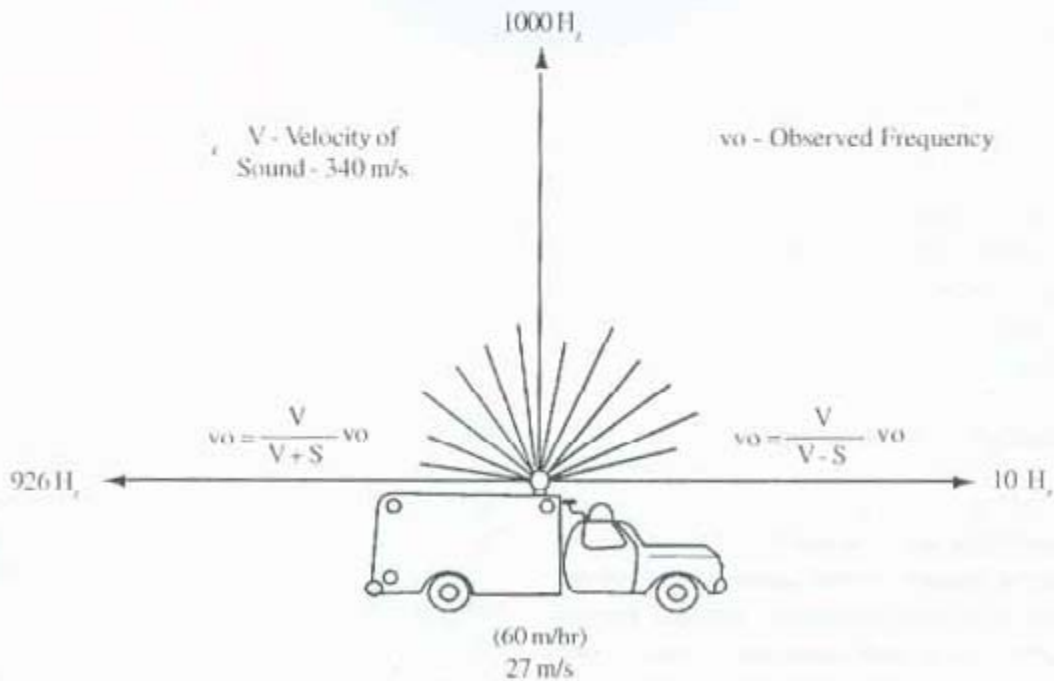
or at least a major portion of it thereby none or very little of it is available for further imaging which is seen as our inability to see structures beyond these interfaces.

Transducers must be directly coupled to the patients skin without an air gap. This coupling is accomplished by means of the gel used while scanning.

Ultrasound Display: It is an electronic representation of data generated from the returning echoes on a TV monitor.

The A mode or the amplitude mode display contains information about the depth of structures

Fig 2 Doppler Principle



and the amplitude of the returning echoes. It is commonly used in ophthalmology.

The TM mode of the timed motion is used in echocardiography.

The B mode produces a picture of a slice of tissue. It took a major step forward with the advent of gray scale imaging. Gray scale depicts the greater variation in the amplitude of the echoes arising from tissues as varying shades of gray.

Doppler

The Doppler principle states that there is a change in the frequency of the sound if there is motion of the source of the receiver or reflector. A typical example of this effect is the change in the pitch of a train whistle as it moves past a stationary observer.

In medical imaging it is this frequency shift of the reflected sound that helps us determine the velocity of blood flow. Fig-2. The Doppler machine can give information about blood flow in the form of an audio signal, a graphic spectrum or color coded information which is superimposed on a gray scale image and is popularly called color flow imaging [2].

Advantages of ultrasound

USG is readily available in most setups and requires little patient preparation. The preparation needed is generally a full bladder to evaluate the pelvis or a fasting patient to evaluate the gall bladder. It is a noninvasive investigation, there being no use of ionizing radiations and has been found to be an ideal imaging modality in the

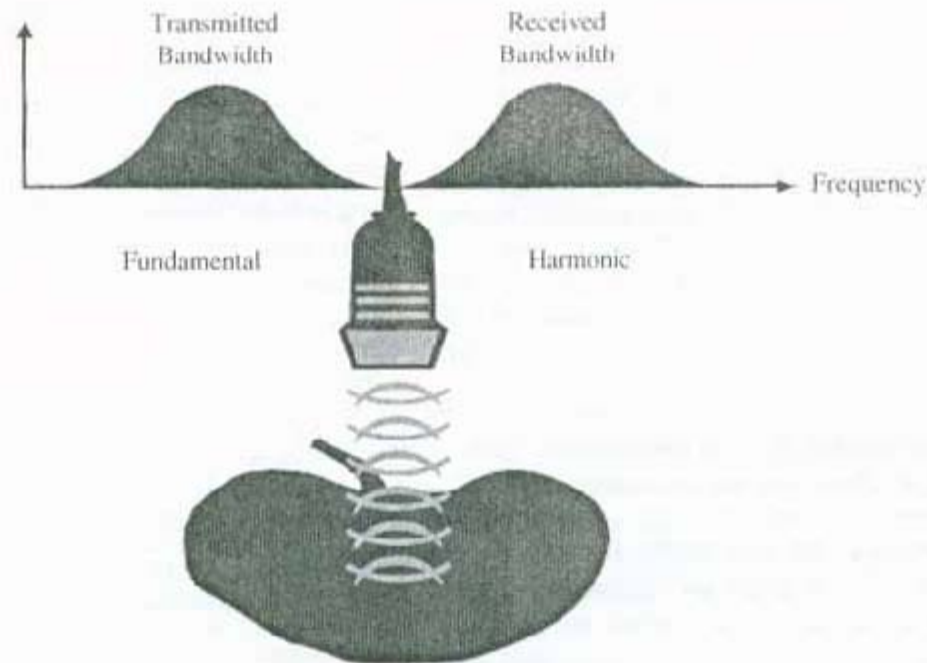
antenatal set up. It is proving an important aid in localizing lesions when tissue diagnosis is required. USG is most useful in differentiating solid from cystic structures.

Newer trends

Harmonic Imaging: Previous research showed that ultrasound propagating through water produces acoustic energy at multiples of the transmitted frequency. These multiples are known as "harmonics". These high frequency low amplitude signals are extremely small. It has long been shown that both tissue and contrast agents generate harmonic energy. Ultrasound systems in the past lacked the sensitivity, band width and the dynamic range to detect these. Newer software developments designed to increase beamformer sensitivity have made this low energy detectable for both contrast agents and body tissues. Ultrasound contrast agents are essentially microbubbles suspended in solution. When these are insonated, they reflect both the fundamental and harmonic frequencies. By programming the system to receive only the harmonic signals, the contrast agent can be better visualized. **Contrast harmonic imaging** has made great inroads in the field of echocardiography.

Tissue harmonic imaging is a product of asymmetric distortion of tissue by an ultrasound wave. Because a tissue expands and compresses unevenly in response to ultrasound, the propagated waveform includes frequencies which are at multiples or harmonics of the transmitted frequency. These harmonics are used to generate the image. The clinical benefits of **native tissue harmonic imaging (NTHI)** are better visualization of tissue interfaces, especially in the technically difficult patients [3]. There is dramatic reduction of haze, clutter and image artifacts.

Fig 3 Tissue Harmonic Imaging



Pulse Inversion Harmonics involves digital storing of the returning fundamental signal as well as its harmonic component. The fundamental signal is then cancelled by a reverse pulse while their harmonic components combine and reinforce. The gains in sensitivity allows the use of smaller amounts of contrast.

Broad band Digital Beam forming and Extended Signal Processing is a technique having fundamental advantages over diagnostic ultrasound by utilizing the full range of ultrasound frequencies. Each tissue in the body responds to ultrasound energy of different frequencies in a characteristic

way, often referred to as the tissue signature. The tissue signature information is carried within a spectrum of frequencies returning from the tissue called the spectrum band width. Broadband digital imaging preserves the quality and quantity of vital tissue signatures by preservation of the entire bandwidth.

Other newer ultrasound techniques like pulse inversion harmonics, power contrast harmonic imaging, microfine imaging, broadband flow imaging, power contrast harmonic imaging are not used routinely. The 3D ultrasound has also been developed and is a more natural way to view

anatomic structures and pathologies and is therefore easier for the referring physicians to understand.

Microfine Imaging combines a broadband digital beamformer with advanced signal processing modules into a supercomputed IPU (Image Processing Unit) resulting in significant performance enhancements for grayscale imaging.

Broadband Flow Imaging brings the resolution advantages of broadband beamforming and more accurate velocity determination to color flow imaging.

Power Doppler allows us to pick up very low flow without information on the direction.

Power Contrast harmonic Imaging is the combination of harmonic imaging with power Doppler technology and offers the ability to differentiate contrast agent and blood from tissue

by detecting further characteristics of microbubble behaviour. It has significantly enhanced the left ventricular border definition on technically difficult patients.

3D Ultrasound Imaging promises to provide better and more efficient methods of displaying diagnostic data. It is a more natural way to view anatomic structures and pathology. 3D ultrasound capabilities that use volume rendering, a relatively new development, are particularly well suited to ultrasound images.

References

1. David O Cosgrove;Ultrasound:General principles. Diagnostic Radiology,Grainger and Alison,3rd edition,83-95
2. TR Nelson, DH Pretorius; The Doppler Signal: Where does it come from and what does it mean. AJR Sep 88 .151,439-447
3. Dresser TS, Jeffrey RB, Lane MJ. Tissue harmonic imaging - utility in abdominal and pelvic sonography. Journal of clinical ultrasound 1999; 27(3): 135 - 141.